Kidney Mobilization and Ultrasound Documentation

By Jacques-Marie Michallet[1]

Introduction

When the time came to choose a dissertation topic, my advisor, Jean-Pierre Barral, suggested that I do some research that would try to document in a scientific manner the results of an osteopathic technique. While the subjective improvement obtained by our treatments has been recognized by almost everyone, we are often criticized for failing to provide evidence that our actions have any objective effect.

M. Barral has been very interested in the kidneys for several years. During that time he has used such imaging techniques as fluoroscopy and intravenous pyelography (IVP) to demonstrate that when the kidneys develop ptosis or prolapse, there is a decrease in their mobility (i.e., their passive motion in response to breathing). He has also endeavored to show that this ptosis and decrease in mobility is often the source of such problems as recurrent urinary tract infections and renal lithiasis (due to dysfunctions in the flow of urine), and pain in the lower back and knees (due to irritation or compression of nerves). In addition, it is sometimes implicated in the development of hypertension and vascular problems of the kidneys themselves, or in venous flow upstream of the kidneys (such as those affecting the left testicular or ovarian veins).

M. Barral has shown that manipulation of the kidneys can relieve these problems, and has clearly demonstrated that the beneficial effects of manipulation are due to the return of normal kidney mobility, rather than the return to a normal anatomical position. This is because on follow-up radiographs, the kidneys have usually to some extent slipped back to the ptosed position. While it might be possible to use serial IVPs to demonstrate the effects of manipulation, there are a few major drawbacks to this method: they primarily

1. Thesis for the Diploma in Osteopathy at the European School of Osteopathy, Maidstone, Kent, United Kingdom, 1986. Edited and reprinted with the permission of the author.

measure position, which is not our goal; there is a risk of sensitivity to the contrast material, which can be life-threatening; and adequate testing before and after manipulation as well as on follow-ups would require too much radiation exposure for the subjects.

We therefore decided to use ultrasound, which does not present the risks of X-rays. The pictures obtained via ultrasound, however, appear as slices or sections of the body, and the kidneys cannot be located in relation to bony landmarks because such landmarks do not always appear in the section. To solve this problem, we then contacted a radiologist in Grenoble, Serge Cohen, M.D., whose competence and generosity had been utilized in M. Barral's earlier experiments. After due consideration, he suggested that it would be easy to measure the amount a kidney moved if we compared it to itself. When ultrasound is performed, two small crosses appear on the screen. These crosses are moveable. When they are aligned with two points on the screen, the machine automatically measures the distance between the two points, which is displayed on the screen in millimeters.

This enabled us to precisely measure kidney mobility by using the following method. One cross marker was aligned with a pole of the kidney at the end of inhalation. The other marker was aligned with the same pole at the end of exhalation. The machine then displayed the distance between these two points, which represented the mobility of that kidney. After making this measurement, we manipulated the kidney and then measured the mobility again in order to document the difference, if any.

On some of the photographs below, the small cross does not perfectly correspond to the edge of the renal pole. This is because there is a short interval between the time that one releases the handle to take the picture and when the picture is taken. Some patients were unable to hold their breath completely during this interval, which resulted in some movement. However, the measurements made by Dr. Cohen were correct and precise as he did align the crosses exactly with the edge of the renal pole before releasing the handle.

Anatomy and Physiology

Because this report is designed for practitioners who already have a good understanding of the anatomy and physiology of the kidney, I will only describe a few of the most important facts pertaining to kidney mobility.

- The kidney has no firm means of support (the pedicle of the kidney is incapable of serving this function). It has no suspensory ligament and no mesentery. The two main factors that prevent the kidney from falling down from its own weight are the "suction" of the thorax and the tension supplied by the anterior abdominal wall. The perirenal fat itself plays a supplementary role, as shown by the fact that when it is reduced suddenly it can be a factor in the development of renal ptosis.
- During inhalation the kidneys are pushed inferiorly along the "rail" of the psoas by the diaphragm. This gives them an oblique motion inferiorly and laterally with inhalation, and superiorly and medially with exhalation. The extent of this motion with deep inhalation and exhalation is between 5cm and 10cm, depending on the person.

In addition, when looking at a kidney ultrasound one can see that the superior pole is pushed forward by the diaphragm. Generally this motion is much less than the inferior and lateral motion, but it can be significant is some cases. We will see later that when this anterior rocking motion of the kidney is strong, it reduces the vertical amplitude of renal mobility.

- There are a multitude of factors that can reduce renal mobility. The most common are intervertebral (from T10 to L1) or costovertebral (R11 and R12) restrictions; gastric ptosis; inflammation or adhesion of a colic flexure; and renal ptosis, whether congenital (we will see such a case) or acquired (usually due to the sudden melting away of the perirenal adipose tissue, trauma, or childbirth). The degrees of renal ptosis and their pathophysiology have been fully discussed elsewhere (see *Visceral Manipulation*, p.199).

Experimental Protocol

We selected 25 people who, by our criteria, had markedly decreased mobility of one kidney. This diagnosis was reached by a variety of means: radiology (plain abdominal films or IVP); hypermobility of a kidney on osteopathic exam (primarily local listening); a history of recurrent urinary tract infection; or a history of sciatica or pain that radiated into the knee which did not seem to be due purely to musculoskeletal problems.

To make this study as objective as possible, and therefore to ensure that the measurements be as precise and reproducible as we could make them, it was necessary to define a protocol that would be adhered to in all cases. All right kidneys were measured at their superior pole in the supine position with the probe placed on the anterolateral aspect of the trunk. Left kidneys were measured at their inferior poles in the prone position with the probe placed in a posterolateral position. These positions were chosen after preliminary tests showed that other structures (primarily the cecum and colonic flexures) could otherwise interfere with the results.

In was also necessary to choose a single manipulative technique for the kidney and perform it in the same way in all cases. There are many techniques for manipulating the kidneys. The one we chose is performed with the subject seated, legs hanging unsupported, and hands resting on the knees. The practitioner stands behind the subject with his arms passed under the subject's arms. The subject's head and shoulders are forward bent in order to relax the abdominal wall, and the subject rotates slightly toward the side of the kidney to be manipulated. The practitioner slowly inches his fingers under the inferior pole of the kidney, and then pulls the kidney superiorly and slightly medially. The practitioner pulls while the subject exhales, and maintains this position during inhalation. This is repeated for four or five breathing cycles until a release is perceived. It is important both to be very gentle, so that the patient and the tissues are able to relax, and at the same time firm enough to have some effect.

After performing this technique, ultrasound was repeated in exactly the same manner as before. Two to four months later (depending on the subject's availability), we again repeated the ultrasound measurements. Each subject therefore underwent three measurements: before manipulation, immediately after manipulation, and a few months later.

Note that of the 25 cases described, we examined 24 right and one left kidney.

We believe that this overwhelming preponderance of right kidney problems is reflected in the daily clinical experiences of our colleagues. In any case, it is well known that the majority of ptosed and/or hypomobile kidney problems are found on the right. This is probably due to the mass of the liver weighing on the right kidney, as well as the fact that the right kidney is situated lower in the body than the left.

Cases

The presentation of each case includes the sex, age and pertinent information from the history and physical examination of the subject. We have also presented some examples of the ultrasounds themselves, and the results of treatment.

CASE 1: Mr. R. S., age 38. Thoracolumbar pain with a history of five small calculi seen on IVP a few years ago. The examination revealed a restriction of T12 (which we treated with manipulation) and hypomobility of the right kidney, which was slightly ptosed.

Initial measurement:	41 mm
Measurement after manipulation:	74 mm
Measurement 3 months later:	77 mm

Result: On his returns the patient reported that he no longer had back pain and had resumed athletic activities.

CASE 2: Mr. J. F., age 40. Recurrent thoracolumbar pain. With each acute episode there were restrictions at T11-L1. The history revealed that the episodes came after meals that were rich in meats and cheeses. On examination the right kidney was less mobile than the left.

Initial Measurement:	42 mm
Measurement after manipulation:	97 mm
Measurement 3 months later:	82 mm

Result: On his return, the patient reported no recurrence of pain.

CASE 3: Mrs. D. T., age 50. Recurrent cystitis and thoracolumbar pain. On examination the right kidney was in a slightly lowered position.

Initial Measurement:	74 mm
Measurement after manipulation:	86 mm
Measurement 4 months later:	87 mm

Result: On her return, the patient reported that she continued to have back pain, but no recurrence of cystitis. The gain in mobility was not very significant (12 mm), but the mobility was originally satisfactory and the improvement was sustained for four months.

CASE 4: Mr. J.R., age 53. Atypical thoracolumbar pain. Renal mobility seemed to be reduced on the right side.

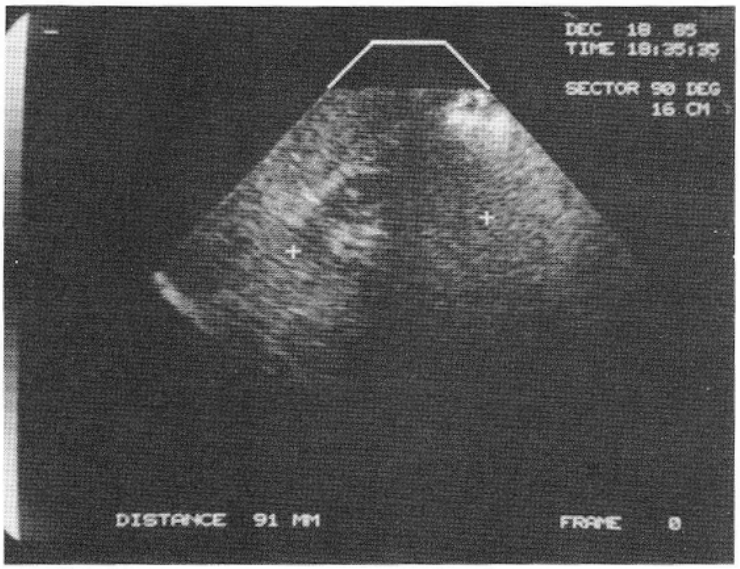

Initial measurement: 91 mm

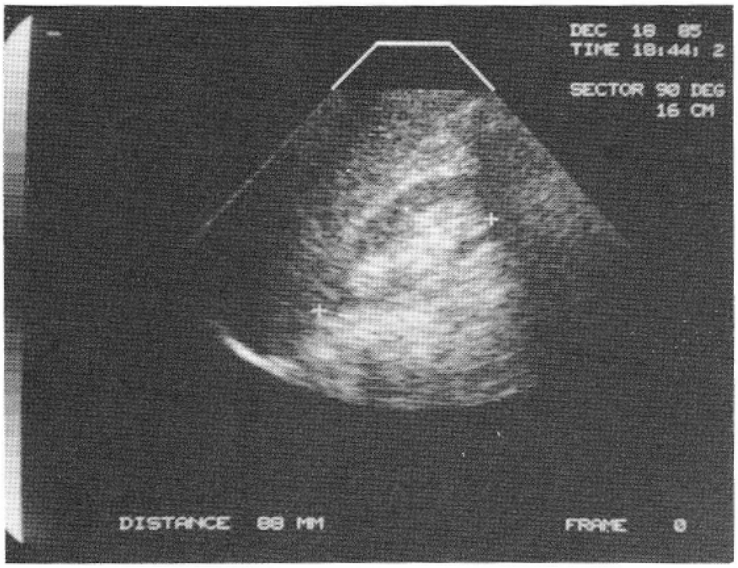

Measurement after manipulation: 88 mm

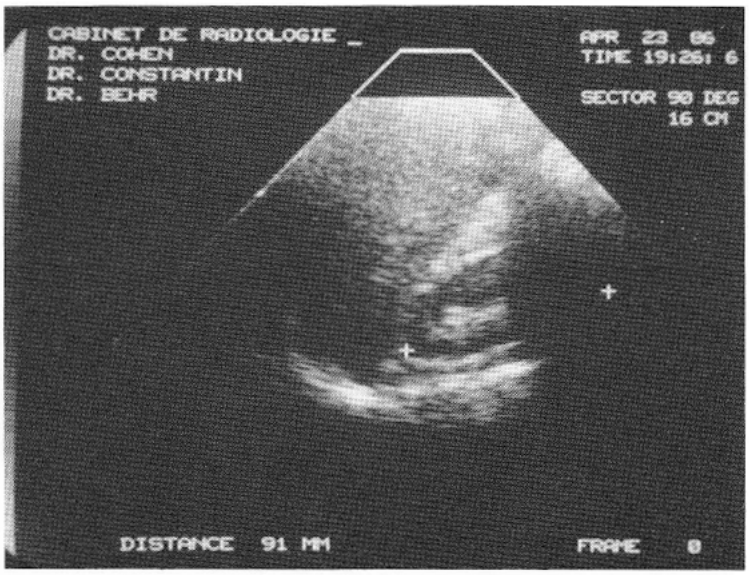

Measurement 4 months later: 91 mm

Result: This is a case of diagnostic error, as the original mobility was excellent. The reason for the small reduction in mobility (3 mm) is unclear, but was perhaps due to stress. In any event, it is comforting to see that four months later the mobility had returned to the original measurement, despite the efforts of the experimenter!

CASE 5: Mrs. M. L., age 58. Thoracolumbar pain with a history of frequent cystitis. On a previous IVP the right kidney had been ptosed.

Initial Measurement:	77 mm
Measurement after manipulation:	85 mm
Measurement 4 months later:	74 mm

Result: The mobility gained after manipulation was lost. The return visit of this patient occured shortly after she had been discharged from the hospital where she had been treated with steroids for a severe asthma attack. We speculate that this may have caused to a decrease in renal mobility.

CASE 6: Mrs. J.C., age 48. Thoracolumbar pain with a history of several attacks of renal colic and urinary tract infections. The right kidney seemed hypomobile.

Initial Measurement:	43 mm
Measurement after manipulation:	Approx. 56 mm
Measurement 4 months later:	61 mm

Results: Measurement immediately after manipulation was difficult due to intestinal gas. It is therefore unclear whether the relative increase between that measurement and four months later is real or artificial.

CASE 7: Ms. N. D., age 38. Atypical thoracolumbar pain with radiation into the knees. On examination the mobility of the kidneys was reduced, especially on the right.

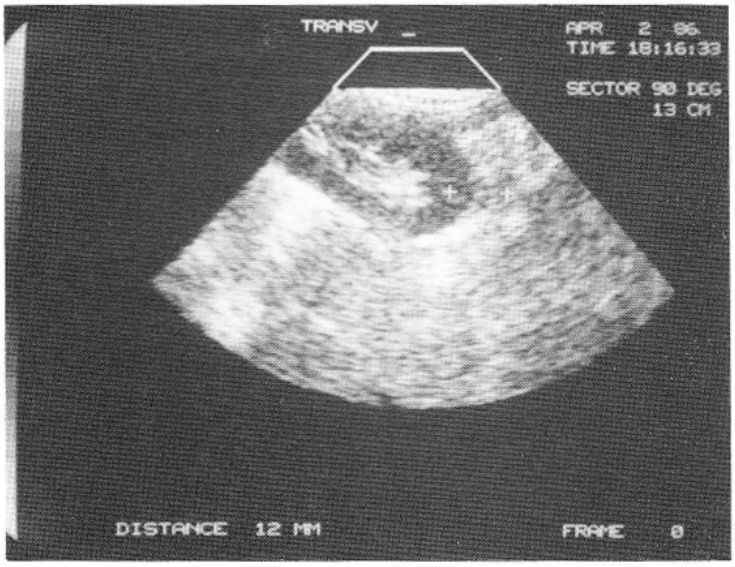

Initial measurement of right kidney: 12 mm

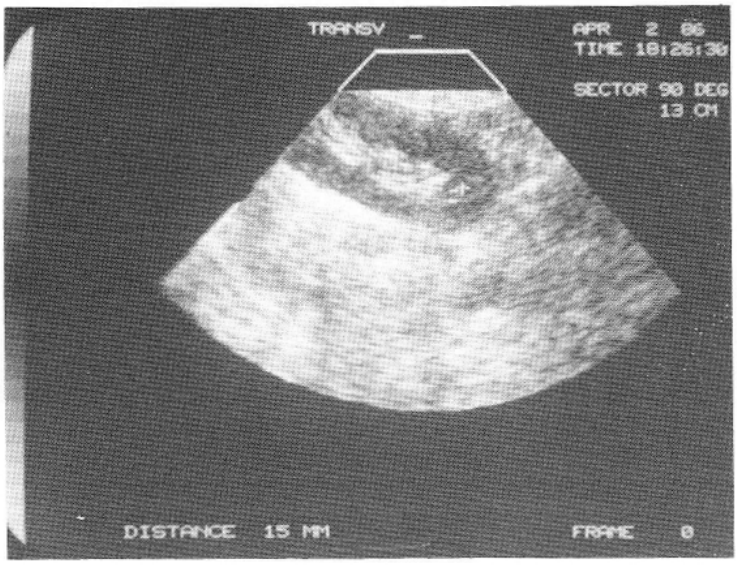

Measurement after manipulation: 15 mm

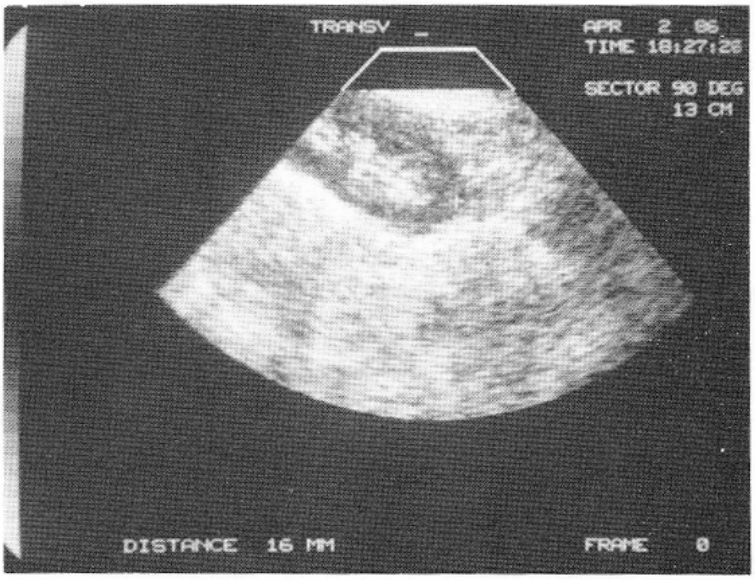

Measurement after manipulation of the left kidney: 16 mm

Results: We measured the mobility of the left kidney here because of the small amount of movement on the right, even after manipulation. Upon closer examination of the movement of these kidneys on the ultrasound screen, we discovered that this small vertical movement was replaced by a very large, anteriorly-directed rotational motion. Unfortunately, we were not able to precisely measure this rotational movement. The patient did return two months later, with no recurrence of back or knee pain.

CASE 8: Ms. M-O. M., age 34. Referred by our colleague, Didier Prat, with a diagnosis of right kidney hypomobility, and very frequent cystitis.

Initial Measurement:	57 mm
Measurement after manipulation:	62 mm
Measurement 4 months later:	59 mm

Results: As in case 7, analysis of the ultrasound screen showed a more significant rotational than vertical movement. On return, the patient stated that she had not had any attacks of cystitis since the last visit. This had not occurred for many years.

CASE 9: Ms. M-J. O., age 33. Referred by our colleagues, J.P. Barral and L. Rommeveaux, for attacks of renal colic and a ptosed right kidney.

Initial Measurement:	43 mm
Measurement after manipulation:	55 mm

Results: Unfortunately, it was not possible for this patient to return at a later date.

CASE 10 Ms. M.C., age 40. Referred by our colleagues, J.P. Barral and L. Rommeveaux, for lower back pain with a diagnosis of left kidney ptosis.

Initial Measurement (prone position):	76 mm
Initial Measurement (upright position):	76 mm
Measurement after manipulation:	104 mm

Results: In this patient the difference in mobility between the prone and upright positions was negligible. The patient was unable to return to the office, but she told us by phone that her back pain had disappeared.

CASE 11: Ms. A., age 44. Referred by our colleagues, J.P. Barral, for right-sided sciatica and knee pain with a diagnosis of right kidney hypomobility.

Initial Measurement:	44 mm
Measurement after manipulation:	47 mm
Measurement 5 months later:	59 mm

Results: The symptoms disappeared a few days after the mobilization of the kidneys, and have not reappeared. Note that there was a further gain in mobility of 12mm after five months.

CASE 12: Ms. N.V., age 49. History of lower back pain with radiation to the right sacroiliac joint and knee. On examination the right kidney felt hypomobile.

Initial Measurement:	38 mm
Measurement after manipulation:	56 mm
Measurement 4 months later:	62 mm

Results: There was both an increase in mobility and a disappearance of the symptoms.

CASE 13: Ms. J.A., age 44. History of atypical knee pain and frequent cystitis. On examination the right kidney felt hypomobile.

Initial Measurement:	58 mm
Measurement after manipulation:	95 mm
Measurement 2½ months later:	104 mm

Results: There was both an increase in mobility and a disappearance of the symptoms.

CASE 14: Mr. J-M. B., age 33. Recent episode of renal colic. Patient had had an IVP after his first episode of renal colic that showed a ptosed right kidney.

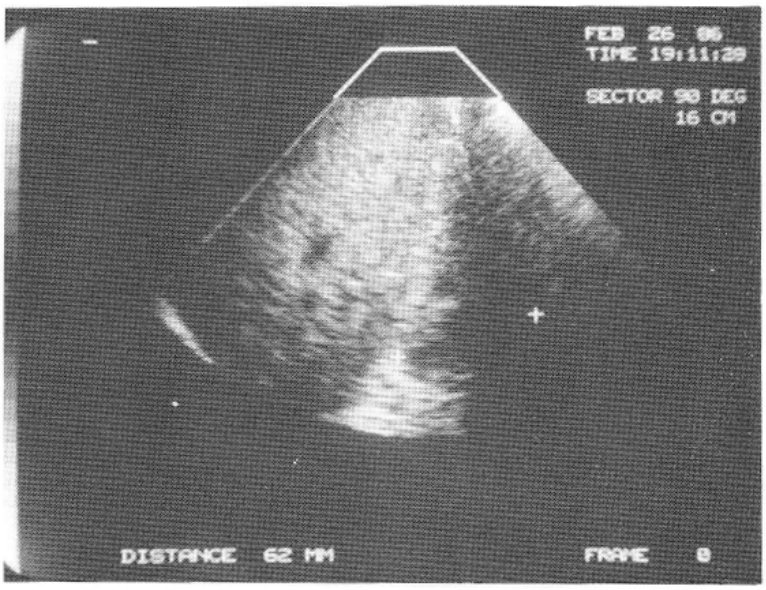

Initial measurement: 62 mm

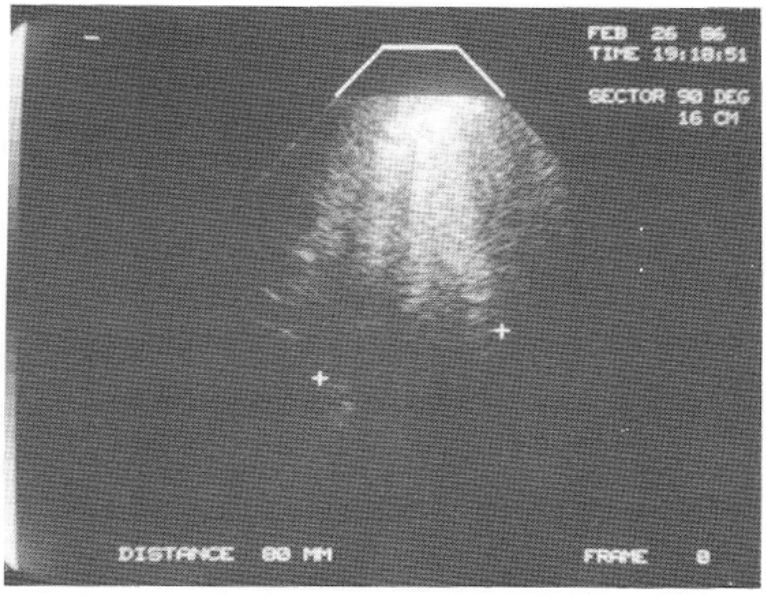

Measurement after manipulation: 80 mm

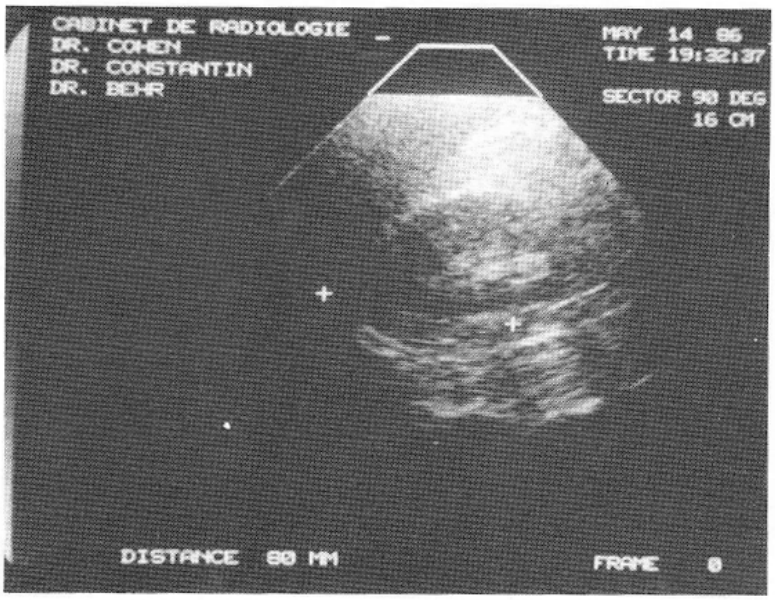

Measurement 2½ months later: 80 mm

Results: This patient had a short and wide body type, which we call brevilinear. This type of person has relatively less motion of his organs, so an increase in mobility of 18 mm was quite satisfactory.

CASE 15: Mr. C. A., age 47. History of a thoracolumbar pain which did not seem to be strictly due to musculoskeletal causes. On examination the right kidney felt hypomobile.

Initial Measurement:	60 mm
Measurement after manipulation:	63 mm
Measurement 3½ months later:	73 mm

Results: While the gain in mobility immediately brought about by manipulation was very small, the total increase was satisfactory.

CASE 16: Ms. B. B., age 28. History of frequent cystitis. An old IVP showed a ptosed right kidney.

Initial Measurement:	64 mm
Measurement after manipulation:	73 mm
Measurement 2 months later:	100 mm

Results: The increase in mobility that occured over two months was much greater than that from the initial response to manipulation. The symptoms of cystitis also disappeared.

CASE 17 Mr. C. B., age 29. Suffering from back pain. Old abdominal X-rays showed lithiasis of the right kidney.

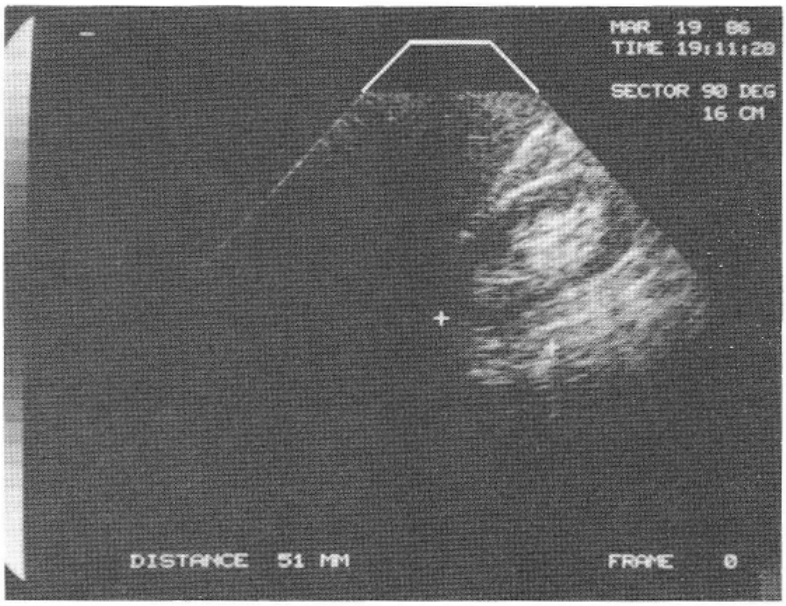

Initial measurement: 51 mm

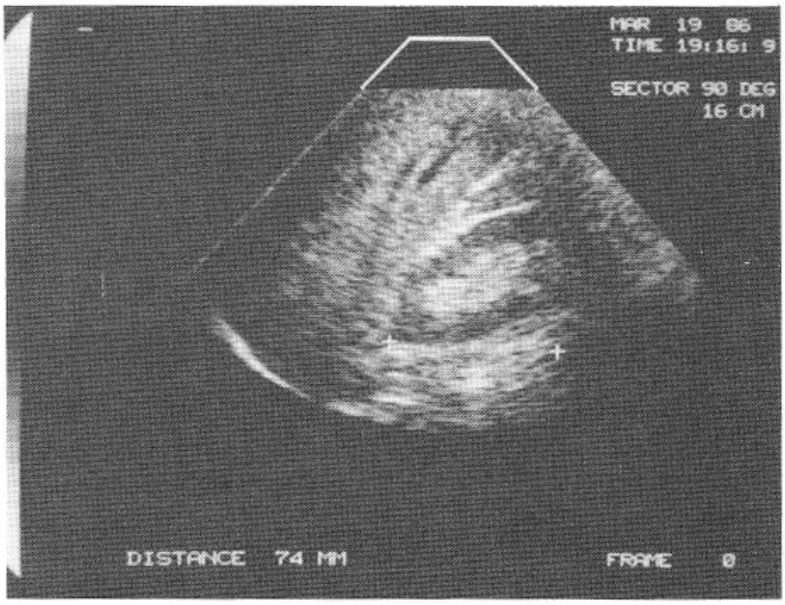

Measurement after manipulation: 74 mm

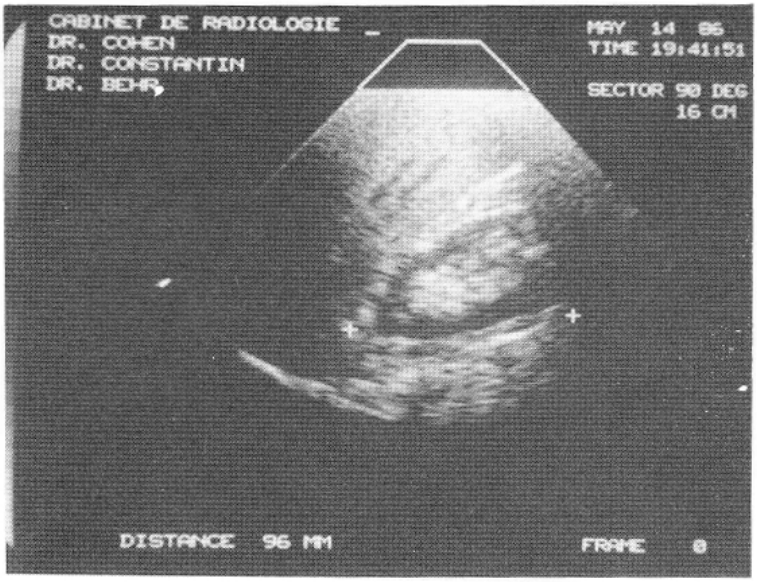

Measurement 2 months later: 96 mm

Results: The total increase in mobility was 45 mm, and the back pain disappeared.

CASE 18: Ms. C. C., age 47. Lower back pain and cystitis. An IVP taken a few years previously showed a ptosed right kidney and a significant bend in the right ureter.

Initial Measurement:	70 mm
Measurement after manipulation:	81 mm

Results: The patient was unable to return to the office for reexamination. She told us by telephone five months after the manipulation that she had no further symptoms of cystitis.

CASE 19: Ms. H. B., age not recorded. Referred by a colleague with a diagnosis of right kidney hypomobility.

Initial Measurement:	50 mm
Measurement after manipulation:	57 mm

Results: The patient was unable to return to the office for reexamination.

CASE 20: Ms. A. D.., age 41. Recurrent cystitis that was particularly severe every spring. On examination the right kidney felt hypomobile.

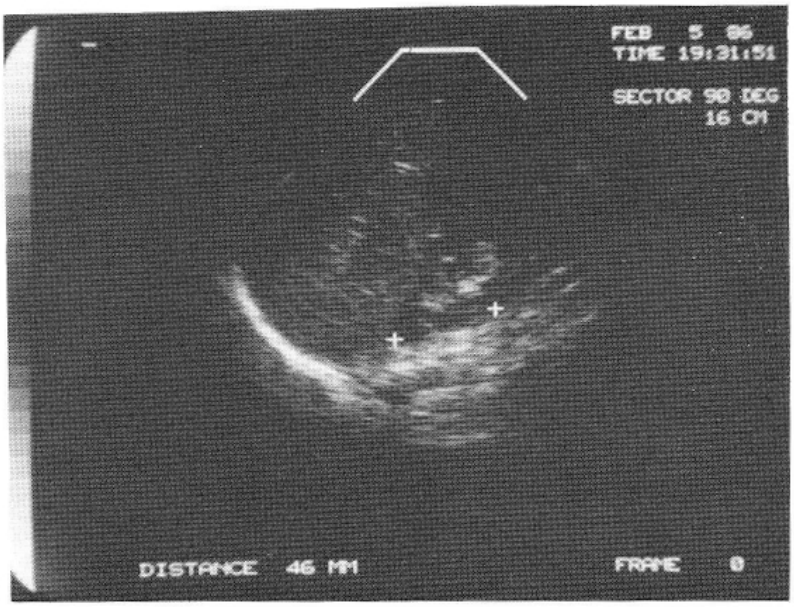

Initial measurement: 46 mm

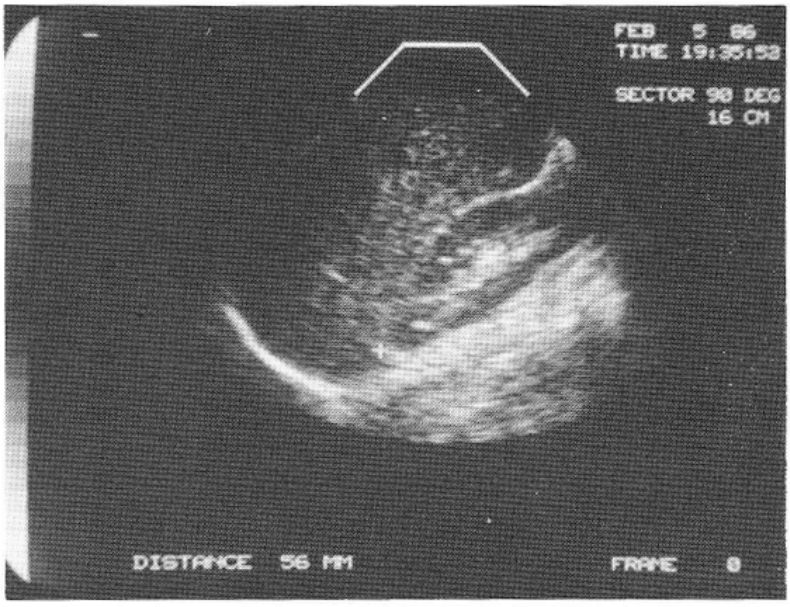

Measurement after manipulation: 56 mm

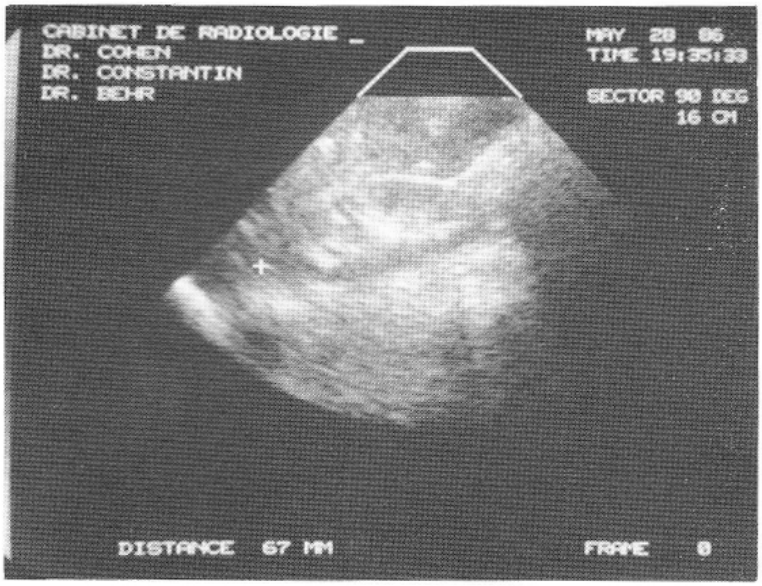

Measurement 3½ months later: 67 mm

Results: This patient was first seen in late winter. Since then she did not have any episodes of cystitis.

CASE 21: Mr. M. B., age 49. Atypical knee pain. On examination it was felt that the right kidney was hypomobile.

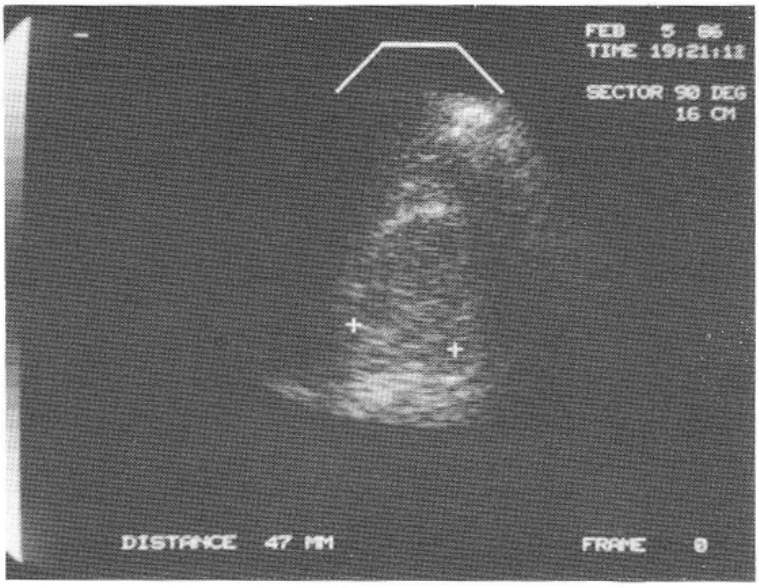

Initial measurement: 47 mm

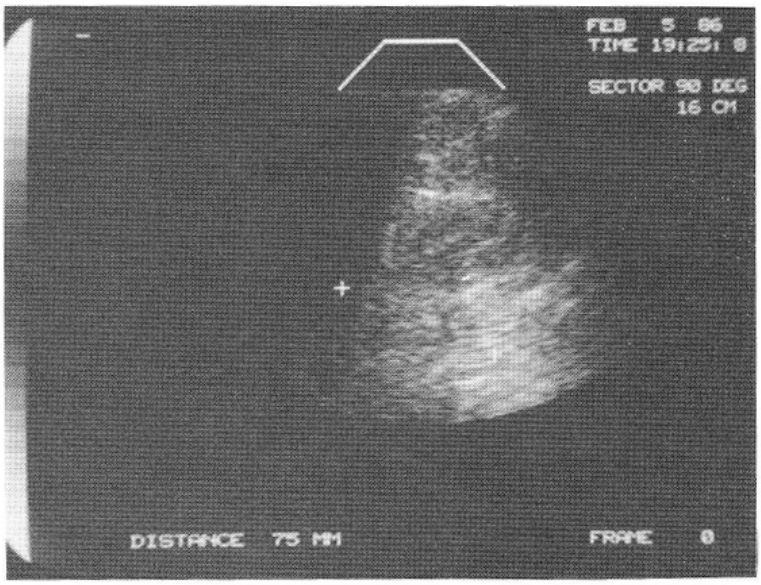

Measurement after manipulation: 75 mm

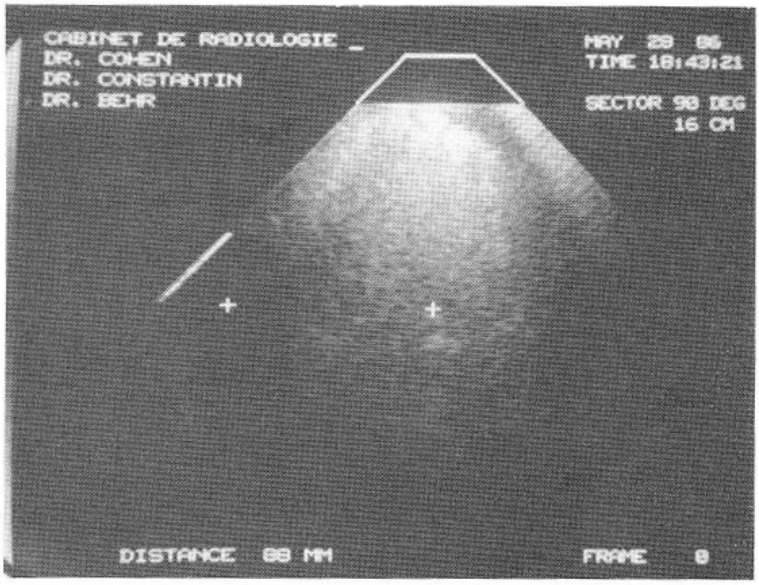

Measurement 3½ months later: 88 mm

Results: After treatment the knee pain disappeared and the patient was able to return to cycling, his favorite sport.

CASE 22 Ms. S. M., age 33. This patient came to be helped with infertility, but the history revealed that she suffered from frequent cystitis. On examination the right kidney felt hypomobile.

Initial Measurement:	27 mm
Measurement after manipulation:	64 mm
Measurement 3 months later:	69 mm

Results: During this period the patient had no episodes of cystitis.

CASE 23: Ms. M-L. A. P., age 59. Right flank pain with radiation into the right knee via the inguinal region.

Initial Measurement:	54 mm
Measurement after manipulation:	73 mm
Measurement 2 months later:	84 mm

Results: On reexamination the patient reported that the right flank and knee pain had disappeared, but that she still occasionally experienced pain in the inguinal region. We felt that this was due to a restriction of T12 and corrected it.

CASE 24: Ms. S. M., age 49. Hypetension with blood pressure of 180/100 mmHg, despite taking an antihypertensive diuretic. On examination the right kidney felt hypomobile.

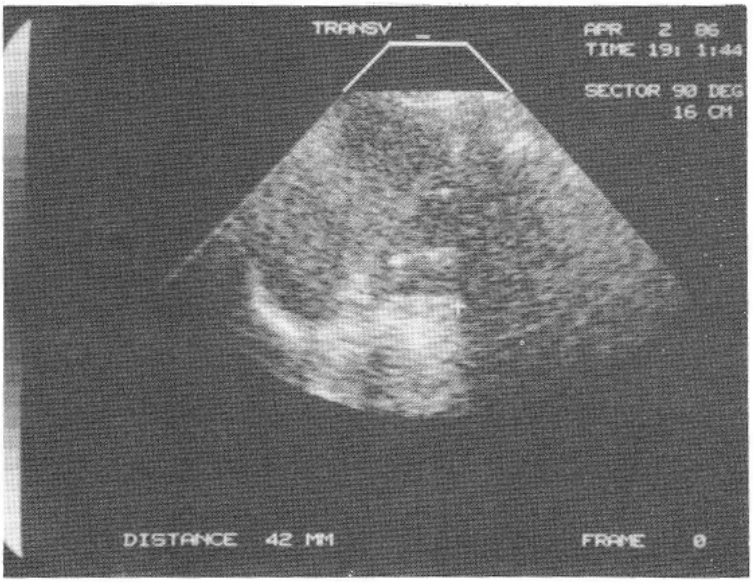

Initial measurement: 42 mm

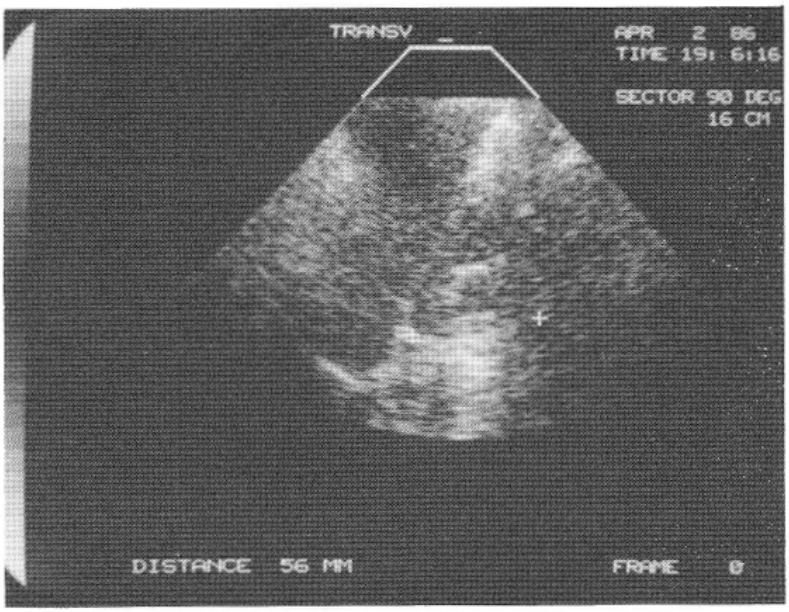

Measurement after manipulation: 56 mm

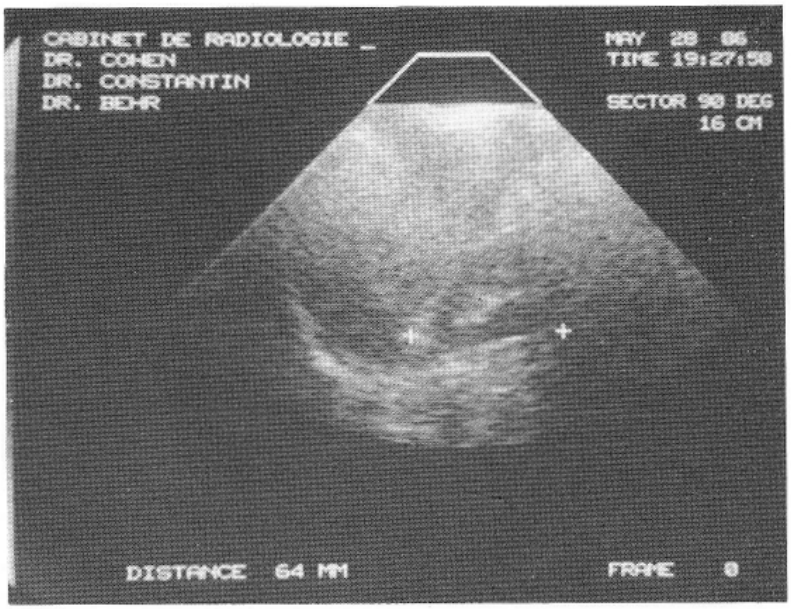

Measurement 2 months later: 64 mm

Results: The patient stopped taking the diuretic the day of the manipulation. On reexamination she reported that her blood pressure had never risen above 140/90 mmHg during the previous two months.

CASE 25: Ms. B. L., age not recorded. Referred by our colleague, Louis Rommeveaux, for verification of a right ectopic kidney, visible by IVP in the right iliac fossa.

Results: On ultrasound the right kidney was completely immobile while the left kidney had compensated by becoming hypertrophic. This is probably a congenital anomaly. No photo of the ultrasound was taken.

Conclusion

Of the cases studied, only two did not manifest a clear and easily measured increase in mobility after manipulation. One of these (case 4) was included in the study by diagnostic error because its mobility was originally well within the range of normal. In the other case (case 25) the kidney was totally fixed and in the iliac fossa so that it could not be reached. This supports our contention that visceral mobility is not only a real phenomena, but one that can be positively influenced by manipulation.

There was definitely variation in the amplitude of mobility. In general, the smallest amplitudes were found among subjects with the smallest stature, while taller subjects had larger amplitudes. This is logical. The average gain in amplitude after manipulation was 17.2 mm (eliminating the cases 4 and 25), with the extremes being 3 mm and 55 mm.

Another important aspect of this study was to measure the lasting effects of renal manipulation, that is, the extent to which the increase in amplitude remained when the subject was reexamined. Of the 23 cases, we were unable to reexamine four and in one other (case 5) the results were probably altered by treatment with large dosages of steroids. Of the remaining 18 cases in which we were able to do a follow-up examination 2-6 months after manipulation, 16 cases showed a further increase in renal mobility, a so-called "delayed reaction." In case 14 the mobility remained unchanged, and in case 2 there was a decrease in 15 mm of the post-treatment mobility, but still an increase of 40 mm in comparison to the pretreatment mobility. The average increase in mobility of these 18 cases at reexamination versus the original measurements was 25.8 mm, that is, 8.6 mm more than the immediate increase in mobility after manipulation. Why does this happen? We believe this is closely related to an adage attributed to the father of osteopathy, A.T. Still: "Find it, fix it, and leave it alone." This means that when we find a lesion or restriction we must treat it *a minima* and let nature do the rest. Once we have given the body the right stimulus, it does the rest on its own. This hypothesis is integral to the framework of osteopathic philosophy.

Acknowledgements

I would like to thank all of our teachers, particularly those who made this study possible, namely Jean-Pierre Barral, Serge Cohen, and Francois Dupont. I would also like to thank my senior colleagues who lavished advice and encouragement on me and my classmates, without whom I may have failed.

From the bottom of my heart I thank my relatives and friends for all their patience and affection during this project, when I badly neglected them.

Finally, I would like to dedicate this work to Louis Michallet, my father, who was a doctor in the noblest sense of the term. I unhappily lost him before I was able to speak to him in a meaningful way about osteopathic medicine. This will always remain the greatest regret in my life.